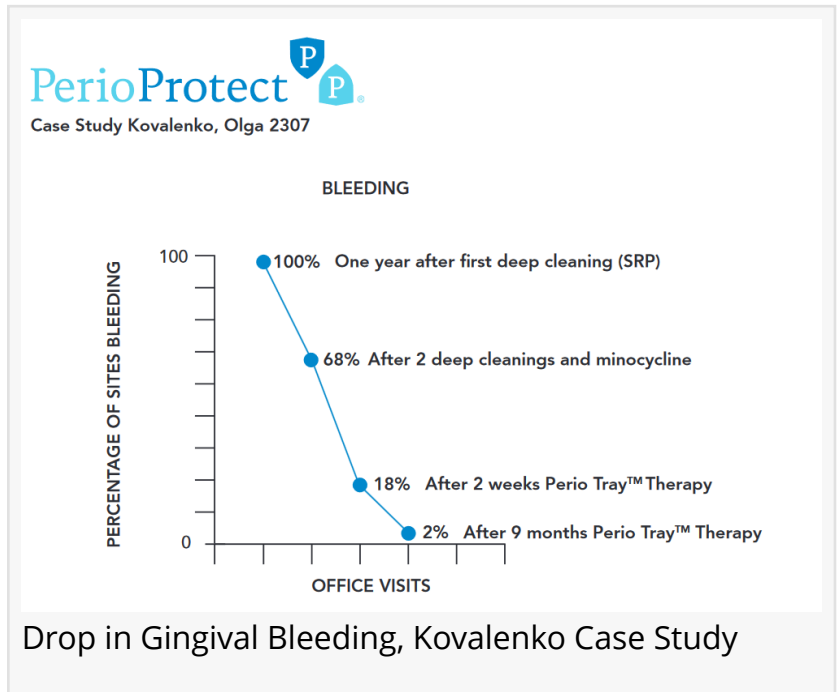


Treating Oral Inflammation with Prescription Perio Tray Homecare Wiped Out Bleeding

After deep cleanings and antibiotics, the patient's gums still bleed at 68% of measured sites. After adding Perio Protect homecare, bleeding dropped to 2%.

ST. LOUIS, MO, USA, October 9, 2023 /EINPresswire.com/ -- Dentists often open a private practice with dreams of using the most advanced education, technologies, and techniques to improve patient health. Once they open those practice doors, they also face new challenges. One of the most common challenges is treating gum disease. Deep cleanings help, but the bacteria repopulate and the infectious cycle persists. This intrinsic difficulty is compounded when patients ghost the dental office.



[This 25-year-old healthy female patient](#) was referred to Dr. Olga Kovalenko in Lynbrook, NY by

“

Not only did the patient's periodontal health improve, but so did her confidence. Now she often showed a full smile.”

Dr. Olga Kovalenko

her boyfriend, whose family had been Dr. Kovalenko's patients. She first visited the office on December 19, 2020 after being absent from dental care for 15 years. She presented with significant plaque and especially both supra and subgingival calculus and was diagnosed with localized moderate to severe gingivitis in the anterior region with possible mouth breathing and localized early periodontitis anterior region (Stage 1 with RBL 2mm below the CEJ). Aggressive Periodontitis (localized Juvenile periodontitis) was suspected due to bone loss being primarily in the anterior dentition.

Scaling and root planing (SRP) was performed on December 21, 2020 and January 11, 2021. Six months later, the patient was referred to a local periodontist who evaluated her condition and treatment planned her for osseous surgery and osseous grafts with selected guided tissue

regeneration (GTR). Due to fear of surgery and financial difficulties the patient postponed the treatment.

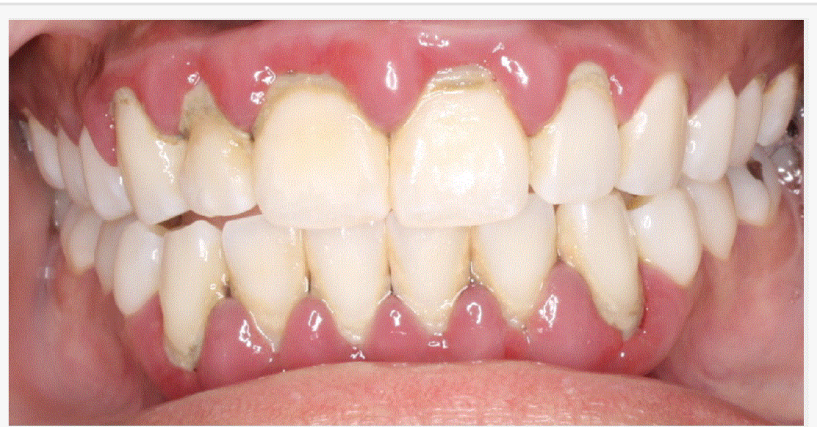When she returned to see Dr. Kovalenko in February 2022, improvements were noted but generalized inflammation remained. Localized SRP was performed with perio maintenance and placement of minocycline in isolated deep pockets on February 26 and March 19, 2022. Patient responded well to treatment but bleeding upon probing persisted.

Four months later, on June 29, 2022, the patient still had 130 sites with bleeding on probing. Dr Kovalenko introduced the patient to periodontal medicament carriers to address the continuing inflammation. She accepted treatment and Rx tray delivery of 1.7% hydrogen peroxide ([Perio Tray™](#) and [Perio Gel™](#), Perio Protect, St. Louis, MO) started on July 20, 2022.

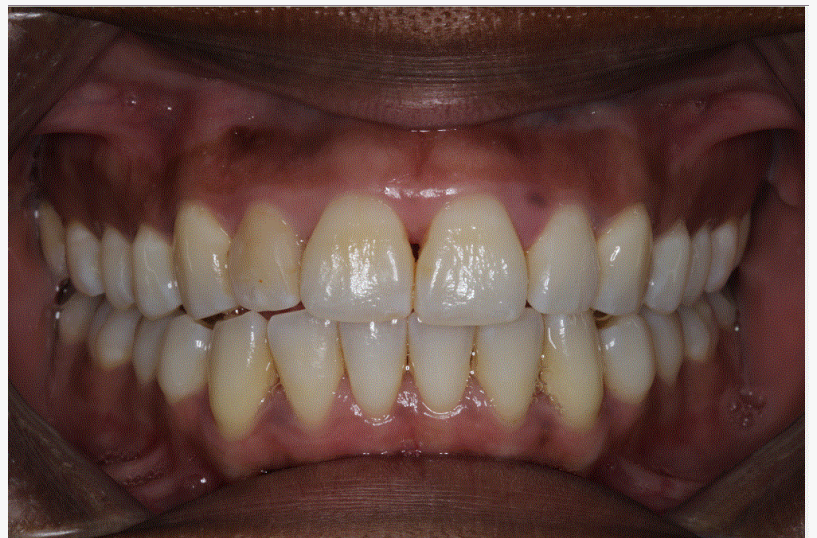She returned to the practice for re-evaluation 14 days later. The effect on the tissue was dramatic. 130 sites with bleeding on probing (68% of all sites) dropped to 34 sites (18% of all sites). The treatment photo shows decreased edematous tissue with more scalloped edges. The patient was very happy with the results. She continued to use her new homecare and when she returned to the office in April 2023, she only had 3 sites with bleeding on probing.

[Not only did the patient's periodontal health improve](#), but so did her confidence. Now she often showed a full smile. Dr. Kovalenko describes her as "more outgoing. She was always friendly," said Dr. Kovalenko, "but the improvements in her health that included fresher breath and whiter teeth transformed her ability to engage with people. It's like she has a new lease on life," explained Dr. Kovalenko. "This is the best part of dentistry, working alongside patients and celebrating their success."

Dr. Kovalenko wanted to become a dentist from the time she was a child. She pursued her dream by coming to New York as a teenager. She graduated Summa Cum Laude from Long Island College, Brooklyn Campus, and subsequently received her doctoral degree from New York



2020 Pretreatment Photo of Swollen, Inflamed Gums



Adding Perio Protect Homecare to Maintenance Appoints Led to Significantly Healthier Gums

University College of Dentistry (NYUCD) where she graduated at the top five percent of her class and was elected to the Omicron Kappa Dental Society.

After graduating from NYU College of Dentistry, Dr. Kovalenko completed a one-year general residency program at Long Island College Hospital (LICH) in Brooklyn, NY and continued her education by taking extensive continuing education courses. These courses included advanced training in Invisalign, cosmetic dentistry, occlusion (Full Mouth Rehabilitation at NYUCD), implant surgery and bone grafting. During this time she developed a vision for her own practice, which she then created.

For more information about Dr. Olga Kovalenko's practice Perfect Smile Dental Arts, please visit <http://perfectsmiledentalarts.com/>. For more information on Perio Protect, please visit, <https://perioprotect.com/how-it-works/>. Research on Perio Tray therapy from Perio Protect, is available at <https://perioprotect.com/claims>.

Tanya Dunlap
Perio Protect
+1 314-256-0772

[email us here](#)

Visit us on social media:

[Facebook](#)

[Twitter](#)

[LinkedIn](#)

[Instagram](#)

[YouTube](#)

This press release can be viewed online at: <https://www.einpresswire.com/article/660644024>

EIN Presswire's priority is source transparency. We do not allow opaque clients, and our editors try to be careful about weeding out false and misleading content. As a user, if you see something we have missed, please do bring it to our attention. Your help is welcome. EIN Presswire, Everyone's Internet News Presswire™, tries to define some of the boundaries that are reasonable in today's world. Please see our Editorial Guidelines for more information.

© 1995-2023 Newsmatics Inc. All Right Reserved.